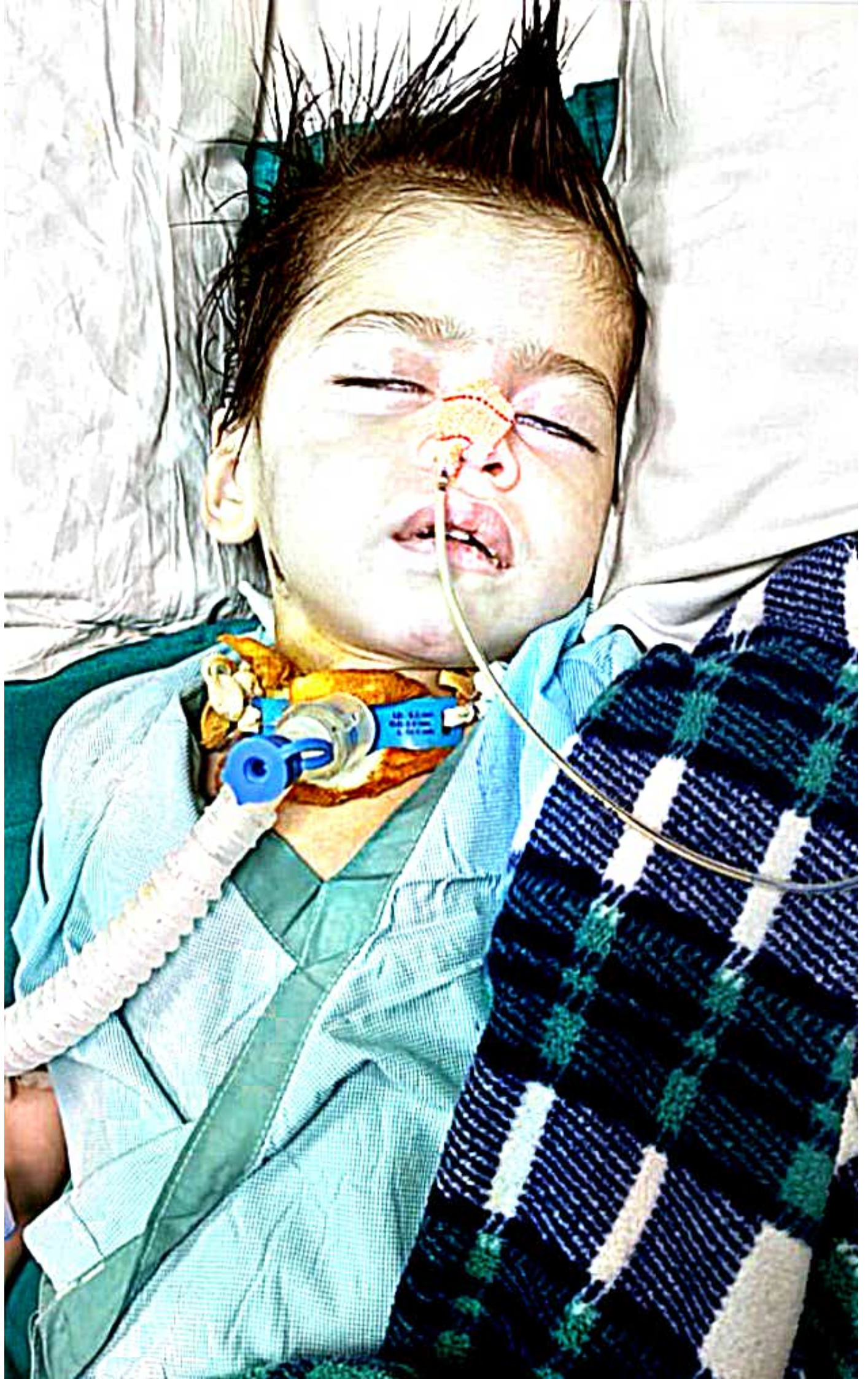



PATIENT SUMMARY

DEPARTMENT OF PEADIATRICS

PATIENT NAME: Baba SIDDHERSHWAR SHARMA

F/H NAME: S/O NAVEEN KUMAR SHARMA

UHID NO : 22-0006461

IPD NO : 22-02967

ADDRESS : 150 VINAYAK VIHAR, TODI NINDAR SIKAR ROAD, ,

CONSULTANT NAME : DR.MANJEET SINGH /DR. ABHIJEET ARI

DATE OF ADMISSION: 07-03-2023 7:12PM

DATE OF SUMMARY: 23-03-2023 / 12:30PM

AGE / SEX : 2 Y/M

CATEGORY : CASH CATEGORY

FINAL DIAGNOSIS: -

1. Polytrauma
2. Diffuse axonal injury leading to hypoxic ischemic encephalopathy
3. C1-C2 cervical spinal cord contusion
4. Odontoid process fracture
5. Quadriplegia
6. Respiratory failure because of cervical cord contusion
7. On Tracheostomy & CPAP
8. Left diaphragm injury
9. Refractory status epilepticus
10. Pressure sores around the neck & sacral area
11. On NG Feed

PROBLEM ENCOUNTERED DURING HOSPITAL

1. Respiratory distress requirement mechanical ventilation
2. Extubation failure
3. Difficult IV access
4. Placement of central line
5. Placement of arterial line
6. Lung contusion
7. Inotropic support
8. Required high dose sedation
9. Pressure sore
10. Multiple imaging
11. Transported for MRI Brain

CHIEF COMPLAINT:-Presented at emergency with alleged H/O fall from terrace almost 12feet height on road at 6:30pm on 07/03/2023 followed by unconsciousness and bleeding from mouth for which taken to near by hospital where intubated and initial treatment was given and referred to DMICC for further care.

आधार

UNIQUE IDENTIFICATION AUTHORITY OF INDIA

पता: S/O: लल्लू राम शर्मा, भिनवानो की
डाणी, मोरिजा, मोरिजा, जयपुर, मोरिजा,
राजस्थान, 303805

Address: S/O: Lallu Ram Sharma,
bhinwalo ki dhani, morija, Morija,
Jaipur, Morija, Rajasthan, 303805



1947
1600 180 1947



help@uidai.gov.in

WWW

www.uidai.gov.in



P.O. Box No.1947,
Bengaluru-560 001



भारत सरकार
GOVERNMENT OF INDIA

नवीन कुमार शर्मा

Naveen Kumar Sharma

जन्म वर्ष / Year of Birth : 1990

पुरुष / Male



(Plain & contrast)= MPRESSION:

- ☑ Collapse consolidation seen in bilateral lower lobes with mild bilateral pleural effusion.
 - ☑ Elevation of left hemidiaphragm is seen, however no evidence of any diaphragmatic hernia seen.
 - ☑ Minimal ascites is seen.
 - ☑ Mild pericholecystic edema seen.
 - ☑ Small caliber of abdominal aorta seen without any thrombus.
- Suggested clinical correlation.

11-03-23 MRI- BRAIN

- Bilateral symmetrical restricted diffusion and cytotoxic edema seen diffusely involving bilateral cerebral hemispheres. Cortical and subcortical regions, basal ganglia with effaced overlying sulci and partial effacement of lateral ventricle s/o acute diffuse hypoxic ischemic encephalopathy.
- No abnormal contrast enhancement seen.
- Transverse fracture of lower part of odontoid process seen with posterior displacement of distal fracture fragment causing compression over thecal sac and spinal cord with cord contusion and edema.

22-03-2023 MRI- CERVICAL SPINE

- Fracture of upper part of odontoid process seen with no evident displacement in present scan.
- Hyperintensity on T2w images seen in spinal cord parenchyma at this level s/o sequel of cord contusion.

22-03-2023 MRI BRAIN

- Hyperintensity on t2w and flair image involving bilateral basal ganglia, thalami, anterior midbrain and cerebral cortices with patchy restricted diffusion s/o hypoxic / ischemic encephalopathy.

CONDITION CONDITION :-

A & B: RR =30/min, SPO2 =98% ON MEC CPAP FIO2=30% PRESSURE =8 SCR -,

C: HR=130/MIN. B.P.=110/64mmHg, CRT <3sec, PP+

D: EYE OPENING

G: ON NG FEED 80ML/2HOURLY

Current Weight= 12kg

CURRENT MEDICATION=

SYP ODOXIL 250 MG 3.6 ML NG Q 12 HOURLY

NEB COLLISTIN Q 12 HOURLY

SYP LEVIPIL 2 ML NG Q 12 HOURLY

SYP ZINCOVIT 5 ML PO OD

DROP ARBIVIT-3 FOR 1 ML PO NG OD

D-RISE SACHET 60K 1 SACHET EVERY 10TH DAY


SYP TONOFERON 5 ML NG OD

SYP GARDINAL 10 MG NG Q 12 HOURLY

SYP CLARIVID -125MG 3.6 ML NG Q 12 HOURLY

Dr. MANJEET SINGH
MBBS, MD, FNB, PEDIATRIC
PEDIATRIC, INTENSIVE CARE
RMC Reg. No. 022809

DR. Manjeet Singh
MBBS, MD,
FIAP, FNB
Consultant Intensivist


Dr. Achijit Ari
MBBS, MD, FNB-PIC
Fellow RCPCH(London)
Consultant Intensivist

DR. Sahaj Prajapati
MBBS, MS
MCh (Pediatricsurgeon)
Consultant surgeon

SYP ODOXIL 250 MG 3.6 ML NG Q 12 HOURLY
NEB COLLISTIN Q 12 HOURLY
SYP LEVIPIL 2 ML NG Q 12 HOURLY
SYP ZINCOVIT 5 ML PO OD
DROP ARBIVIT-3 FOR 1 ML PO NG OD
D-RISE SACHET 60K 1 SACHET EVERY 10TH DAY
SYP TONOFERON 5 ML NG OD
SYP GARDINAL 10 MG NG Q 12 HOURLY
SYP CLARIVID 125MG 3.6 ML NG Q 12 HOURLY
SYP PIRACETAM ML RT Q 12 HOURLY
TAB VITFOL PLUS 10 D RT Q 24 HOURLY
GROVIVA POWDER Q 12 HOURLY
ZYTE MOUTH COLLITINE ORAL Q 8 HOURLY
INJ DEXONA 1.5 MG IV Q 24 HOURLY
INJ COLISTIN 3 LACK IV Q 8 HOURLY UNIT
INJ CEFIPIME 600 MG IV Q 12 HOURLY
INJ PCM 180, G IV SOS
SYP PICLIN 5 ML RT Q 12 HOURLY

INVESTIGATION:-

ATTACHED ORIGINAL

07/03/23 CT – BRAIN (PLAIN) =IMPRESSION:

- ☑ No significant abnormality seen in brain parenchyma.
- ☑ No evidence of acute hemorrhage or space occupying lesion, calcification or hydrocephalus seen.

Suggested clinical correlation.

07/03/23 NCCT THORAX= IMPRESSION:

- ☑ Collapse seen in left lower lobe with very minimal left pleural collection.
- ☑ Elevation of left hemidiaphragm is seen.
- ☑ Fibro atelectatic changes are seen in right upper lobe.

Suggested clinical correlation.

07/03/23 NCCT SCAN OF NECK=IMPRESSION:

- ☑ Endotracheal tube seen in situ.
- ☑ Mild adenoid hypertrophy seen.
- ☑ Slightly anteriorly displaced fracture of base of dens is seen without any canal stenosis or cord compression.

07/03/23 NCCT – ABDOMEN & PELVIS= IMPRESSION:

- ☑ Mild ascites.

Suggested clinical correlation.

09/03/23 CT – ABDOMEN & PELVIS

मेरा नाम नवीन कुमार शर्मा है मैं गौरिजा, जयपुर का रहने वाला हूँ।
 मेरा 2 वर्ष का बेटा मिश्रा नाम सिद्धेश्वर शर्मा है 07-03-2023 को मेरा
 बेटा बस पर चढ़ाई करे, बस के मचि बिर गमना कात से 12 पीड
 नमि पानी पर गिरने से मेरे बेटे के बिर व फेफड़ों में चोट
 आती है मैंने बेटे को DMCC Hospital, जयपुर में भर्ती करवाना है
 अभी मेरा बेटा ICU में वेंटिलेटर सपोर्ट पर है। डॉक्टर के अनुसार
 मेरे बेटे को ठीक होने में लम्बा समय लग सकता है अभी तक मेरे
 बेटे के इलाज में 65 लाख रुपये से अधिक खर्च हो चुका है मैं जयपुर
 में न्यू हॉर्सेड कंपनी में काम करता हूँ। मैं आपसे संलग्न है अनुरोध
 करता हूँ। कि मेरे बेटे सिद्धेश्वर शर्मा को इलाज में सहायता
 करावता रहे।

आपका

नवीन कुमार

नवीन कुमार शर्मा

उम्र लच्छू राम शर्मा, गिन्वाली की हानी

ग्राम - गौरिजा, तह. - जौहरी

जयपुर, 303805, राजस्थान

हस्ताक्षर विनासी:-

म.अ. 150, विनाजक विहार,

पेडी नीकड़, जयपुर, 302013.

तम.

| | |
|---------|--|
| GIT: | <p>Feeding started and increase as per guideline. CECT abdomen advised in view of diaphragm rupture report suggestive of Mild ascites.</p> <ul style="list-style-type: none"> • Collapse consolidation seen in bilateral lower lobes with mild bilateral pleural effusion. • Elevation of left hemidiaphragm is seen, however no evidence of any diaphragmatic hernia seen. • Minimal ascites is seen. • Mild pericholecystic edema seen. • Small caliber of abdominal aorta seen without any thrombus. <p>Suggested clinical correlation On D3 of admission start feed with 10ml/6hourly with NG feed. Now patient taking 80ml/2hourly feed with NG tube and tolerating. PEG tube has been planned.</p> |
| Sepsis: | Antibiotics was started and upgraded in view of sepsis. |

Counselling: -Parents (Father predominantly) have been counselled on various occasion in relation to current situation & future prognosis of the disease in their own language.

MEDICATIONS DURING HOSPITAL STAY:-

- INJ TAZACT 1 GM IV Q 8 HOURLY
- INJ PCM 180 MG IV Q 8 HOURLY SOS
- DROP MOISOL 2 DROP EYE Q 2 HOURLY
- INJ PANTOP 15 MG IV Q 24 HOURLY
- INJ TRAMEXA 120 MG IV Q 6 HOURLY
- INJ COLISTIN 3 LACK IV Q 8 HOURLY
- INJ MANNITOL 30 ML IV Q 6 HOURLY
- CHLORHERADIN MOUTH WASH Q 12 HOURLY
- INJ LEVIPIL 180 MG IV Q 12 HOURLY
- INJ MEROPENEM 500 MG IV Q 8 HOURLY
- INJ TEICOLPLANIN 100 MG IV Q 24 HOURLY
- INJ PHENOBARBITONE 60 MG IV Q 24 HOURLY
- INJ DEXMETHOSONE 1.8 MG IV Q 12 HOURLY
- INJ GARDENAL 80 MG IV Q 24 HOURLY
- TAB DROP FUIROPED 1.2 ML PO/NG Q 12B HOURLY
- INJ DEXMETHOSONE 1.5 MG IV Q 12 HOURLY
- T-BACT FOR 4 TIMES FOR LOCAL APPLICANT
- INJ MEROPENEM 500 MG IV Q 8 HOURLY
- INJ XONE 600 MG IV Q 12 HOURLY
- MOISOL EYE DROP EYE Q 2 HOURLY
- LACRIGEL EYE OINT EYE Q 12 HOURLY
- LASIX 10 MG IV Q 8 HOURLY

SYSTEMIC EXAMINATION: -

CENTRAL NERVOUS SYSTEM: - Altered Sensorium on sedation

CARDIO VASCULAR SYSTEM: - S1, S2 NORMAL, HR=130/MIN, PHERIPHERY cold , B.P.=98/58(71)mmHg

RESPIRATORY SYSTEM: - INTUBATED B/L UN EQUAL AIR ENTRY, R>L SPO2=85 % ON AMBU RR=50/MIN,

SCR+, RESPIRATORY DISTRESS+

GASTRO INTESTINAL SYSTEM :-P/A SOFT, BS+

SEPSIS= T=98.4F

LOCAL= abrasion injury on sternal area

3cm fresh cut wound on chin

COURSE DURING HOSPITAL STAY: -

| | |
|---------------------|---|
| Neurology: | <p>On admission received with sedation. CT head done suggestive of normal findings. Neurosurgeon opinion was taken advised for conservative treatment. Continue sedation with inj fentanyl and inj medazolam as per prortocol. On day 2 keep off sedation for extubation. But again start sedation by evening as extubation failure. Developed refractory status epilepticus requiring high dose of Phenobarbitones & Midazolam On day 3 Sedation holiday was given to assess neurology status. MRI brain on 11/03/23. Suggestive abnormal finding. Plan for MRI BRAIN and cervical on 22/03/23. Suggestive of DAI Multiple times pediatric neurology and surgeon opinion was taken advised for conservative treatment.</p> |
| Respiratory system: | <p>Received with ETT with AMBU. Immediately put on SIMV-PC Mode of ventilation with high setting. NCCT neck and THORAX advised suggestive of Collapse seen in left lower lobe with very minimal left pleural collection.</p> <ul style="list-style-type: none"> • Elevation of left hemidiaphragm is seen. • Fibro atelectatic changes are seen in right upper lobe <p>Slightly anteriorly displaced fracture of base of dens is seen without any canal stenosis or cord compression. Which was weaned as per condition. On day 2 extubation failure , reintubated and ventilated with same mode and weaned setting. Tracheostomy tube has been placed on 13/03/23 as the child needs prolonged ventilation for poor neurology. Mode changed to CPAP with pressure 8 and maintain saturation. Patient might need prolonged ventilation</p> |
| Cardiovascular: | <p>Not maintain blood pressure so immediately put on inotropes inj noradrenaline (1ml=0.1mcg/kg/min) Inotropes was weaned and off as per patient consition. On maintain blood pressure</p> |
| Renal: | <p>Fluid according to TFI and passing urine normally. On day 2 urine output decreased so inj Lasix infusion was started for 8hours followed by maintenance dose and passing urine normally.</p> |
| GIT: | <p>Feeding started and increase as per guideline. CECT abdomen advised in view of diaphragm rupture report suggestive of Mild ascites.</p> |